

**Patient: 39-year-old female, persistent open wound following radiation and nipple reconstruction due to breast cancer**

**Wound characteristics and prior treatment:**

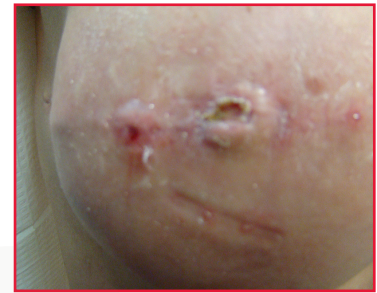- Patient developed rash and partial nipple necrosis in the open post-surgical wound
- Wound measurement: 0.8cm x 0.7cm x 0.3cm deep
- No pain management was needed
- Wound had been previously treated with antibiotic ointment and a petrolatum gauze impregnated with a 3% Bismuth Tribromophenate covered with dry gauze and tape for a once-a-day dressing change. Patient provided self-care.

**Treatment:**

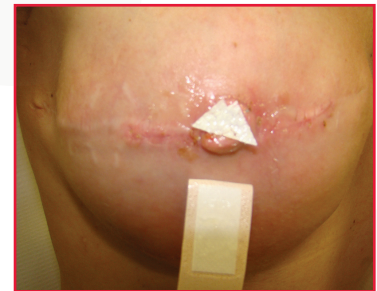
- Patient treated with Endoform dermal template placed on open wound with an antibiotic ointment and an adhesive strip bandage
- Patient replaced the dressing herself 3x per week and was able to shower without difficulty

**Results:**

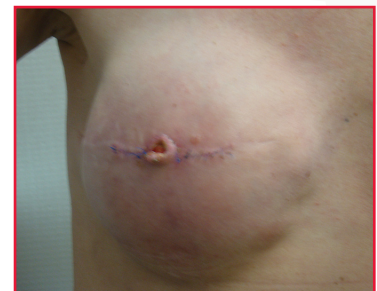- 3 weeks after treatment with Endoform dermal template was initiated, patient returned to the office with the nipple wound re-epithelialized
- No pain management was required
- Treatment goal was met with use of Endoform dermal template



Wound presented measuring 0.8cm x 0.7cm x 0.3cm deep



Endoform dermal template application was performed



In-office closure after 3 weeks in treatment with Endoform dermal template — wound was re-epithelialized



Manufactured for  
**Hollister Wound Care**  
2000 Hollister Drive  
Libertyville, IL 60048  
1.888.740.8999

Distributed in Canada by  
**Hollister Limited**  
95 Mary Street  
Aurora, Ontario L4G 1G3  
1.800.263.7400

[www.hollisterwoundcare.com](http://www.hollisterwoundcare.com)

Case provided by:  
Paul M. Glat, MD, FACS; 191 Presidential Blvd. Suite 101, Bala Cynwyd, PA

**CAUTION:** Federal (USA) Law restricts this device to sale by or on the order of a physician.  
Prior to use, be sure to read the entire Instructions for Use package insert supplied with the product.  
922217-0213

Hollister and Logo is a trademark of Hollister Incorporated.  
Endoform is a trademark of Mesynthes Limited.  
©2013 Hollister Incorporated.